



PATIENT

Zoey Howey

SPECIES

Canine

BREED

Labrador Retriever

SEX

Female Spayed

AGE

4 years

WEIGHT

74.5lbs

INTERPRETED BY

Maggie Machen Lamy,
DVM, DACVIM
(Cardiology)

IMAGING PERFORMED BY

S. Barthelemy, DVM

HOSPITAL NAME

Bridgeland Vet Clinic

REFERRING VET

Dr. Flath

INVOICE

30457

DATE

4/26/23

PRESENTING CLINICAL SIGNS

History: Sudden onset grade 4-5 murmur. Asymptomatic.

ECHOCARDIOGRAM FINDINGS

2D, m-mode, color flow and doppler imaging is available. The left ventricular wall is severely hypertrophied (1.76cm globally). There is a diffusely hyperechoic endocardium consistent with remodeling. Papillary muscle hypertrophy. The left atrium is minimally dilated. The right atrium is normal in size. The right ventricle appears normal. The anterior leaflet of the mitral valve is dysplastic with severe thickening and an elongated leaflet that prolapses into the LVOT in systole (see below). There is mild to moderate mitral regurgitation associated with this abnormal motion. No tricuspid regurgitation seen. Blood flow through the LVOT is severely elevated with a fixed profile. No aortic insufficiency noted. Prominent coronary vessels. No obvious shunts. No evidence of cardiac tumors or metastatic lesions on this scan. No pleural or pericardial effusion seen.

CARDIAC CHART

| CANINE CARDIAC PARAMETERS | MR VMAX (m/s) | TR VMAX (m/s) | LA/AO (Boon method) | LA/AO (Heart Base; Swe) | FS (%) | EF (%) | EPSS (cm) |
|---|---------------|---------------|---------------------|-------------------------|---------------------------------|--|--|
| NORMAL PARAMETER | 4.5-5.5 | <2.7 | 1.3 | <1.6 | 28-40 | 40-100 | <0.6 |
| PATIENT | NM | NA | 1.5 | 1.3 | 59 | 89 | 0.2 |
| CANINE CARDIAC PARAMETERS | HR (BPM) | AV VMAX (m/s) | PV MAX (m/s) | BODY WEIGHT (kg) | LA 2D short axis Base view (cm) | LVIDd Avg; 2D and m-mode short axis (cm) | LVIDs Avg; 2D and m-mode short axis (cm) |
| NORMAL PARAMETER | 50-100 | 0.7-1.7 | 0.7-1.6 | BELOW | BELOW | BELOW | BELOW |
| PATIENT | 100 | 5.8 | 1.0 | 33.8 | 3.1 | 3.3 | 2.1 |
| *Normal chamber parameters expressed as a mean value (SD) | | | | 3 | 1.27 (5.3) | 2.46 (2.46) | 1.36 (5.5) |
| BODY WEIGHT DEPENDENT PARAMETERS | | | | 5 | 1.40 (4.5) | 2.74 (5.2) | 1.60 (4.7) |
| <i>*Note: All measurements based upon multi-modal images and methods. An average value is reported.</i> | | | | 10 | 1.50 (3.8) | 3.27 (3.5) | 2.06 (3.1) |
| | | | | 15 | 1.83 (2.0) | 3.71 (2.4) | 2.43 (2.1) |
| | | | | 20 | 2.02 (1.9) | 4.14 (2.2) | 2.80 (2.0) |
| | | | | 25 | 2.18 (2.4) | 4.48 (2.9) | 3.10 (2.5) |
| | | | | 30 | 2.33 (3.3) | 4.83 (3.9) | 3.39 (3.4) |
| | | | | 35 | 2.48 (4.3) | 5.17 (5.0) | 3.69 (4.5) |
| | | | | 40 | 2.62 (5.2) | 5.48 (6.1) | 3.96 (5.4) |
| | | | | 50 | 2.88 (7.1) | 6.07 (8.3) | 4.46 (7.4) |

Adapted from June Boon, Veterinary Echocardiography, 1998
Rishniw M and Hollis NE, J Vet Intern Med 2000; 14:429-435
Hansson et al, Vet Rad and Ultrasound 2002
Bonagura et al. Echocardiography: principles of interpretation, Vet Clin North Am 15:1177, 1995

INTERPRETATION OF THE FINDINGS & FURTHER RECOMMENDATIONS

The cause of the murmur is mitral valve dysplasia causing an LVOT obstruction and mitral regurgitation. This is similar to SAM in a cat, with hypertrophy of the LV secondary to pressure overload caused by obstruction to flow. The obstruction is likely highly heart rate dependent, which may explain why the murmur is inconsistently appreciated. That being said, this degree of LVH takes time to develop and this is likely a congenital issue. The left atrium is minimally dilated, and additional issues are identified.



PATIENT

Zoey Howey

SPECIES

Canine

BREED

Labrador Retriever

SEX

Female Spayed

AGE

4 years

WEIGHT

74.5lbs

INTERPRETED BY

Maggie Machen Lamy,
DVM, DACVIM
(Cardiology)

**IMAGING
PERFORMED BY**

S. Barthelemy, DVM

HOSPITAL NAME

Bridgeland Vet Clinic

REFERRING VET

Dr. Flath

INVOICE

30457

DATE

4/26/23

Lifelong heart rate control with Atenolol is recommended, as the dynamic nature of the obstruction will be reduced at lower heart rates. No other medications are indicated at this juncture. Mild activity restriction is advised. Monitor at home for any respiratory signs or clinical lethargy/collapse. Prognosis is guarded, as many MVD cases will improve on atenolol however serial monitoring is advised. Given the degree of hypertrophy, this patient does have high risk for arrhythmic sudden death and the owner should be warned of this possibility. Routine ECG monitoring is recommended.

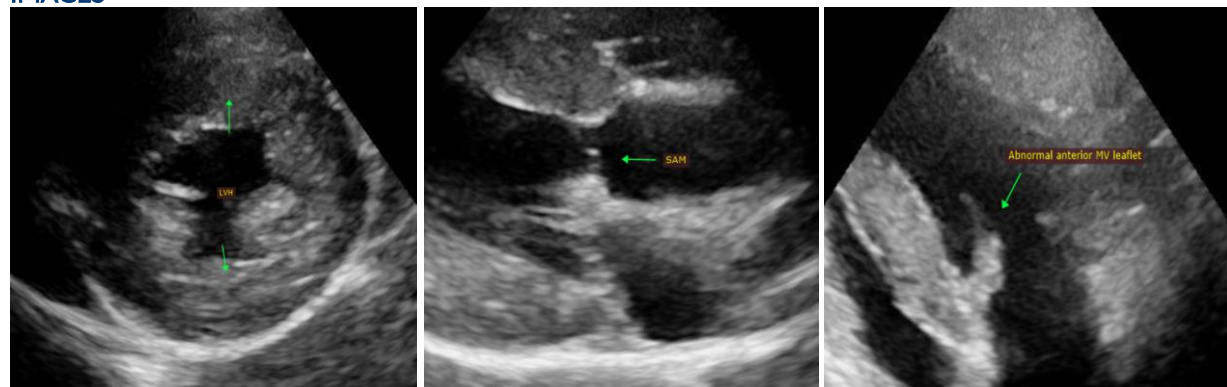
Anesthetic risk is considered moderate if needed. Cardiac protective drug choices (opioid/benzodiazepine premedication, propofol or alfaxalone induction, isoflurane gas) are recommended. Pre-oxygenate for 5-10 minutes prior to induction. Monitor for arrhythmias, hypotension, and hypoxia both intra and post-operatively and intervene as necessary. Mild IV fluid restriction is recommended to avoid fluid overload. **Avoid heart rate stimulating drugs such as atropine unless clinically indicated.**

PLAN

Administer titrating dose of atenolol: 25mg tablets; Give ¼ tab twice daily. Recheck heart rate in 1-2 weeks with target stressed rate of <130bpm, increase as needed until target reached. Lifelong BP and ECG monitoring is advised.

Recommend recheck echocardiogram in 6-12 months to assess response to atenolol, sooner if clinical issues arise.

IMAGES



The information and recommendations provided are based on the images presented by the referring veterinarian. No evaluation can be communicated regarding pathology that was not visible in the image/video clips provided.

Thank you for this referral. This report was generated using transcription software, and minor dictation errors may be present. If the clinical or image interpretation does not parallel your findings or if I can be of any further assistance, please contact me.

Maggie Machen Lamy, DVM
Diplomate of the American College of Veterinary Internal Medicine (Cardiology)
info@sonopath.com